




Available online at  
 ScienceDirect  
 www.sciencedirect.com

Elsevier Masson France  
  
 www.em-consulte.com/en



Original article

## Effect of light-emitting diode (LED) therapy on the development of osteoarthritis (OA) in a rabbit model

Yasushi Oshima<sup>a</sup>, Richard D. Coutts<sup>a</sup>, Neil M. Badlani<sup>a</sup>, Robert M. Healey<sup>a</sup>,  
 Toshikazu Kubo<sup>b</sup>, David Amiel<sup>a,\*</sup>

<sup>a</sup> Department of Orthopaedic Surgery, University of California San Diego, 9500 Gilman Dr, La Jolla CA 92093-0863 USA

<sup>b</sup> Department of Orthopaedics, Graduate School of Medical Science, Kyoto Prefectural University of Medicine, Kyoto 602-8566 Japan

### ARTICLE INFO

#### Article history:

Received 23 November 2010

Accepted 8 February 2011

Available online 20 May 2011

#### Keywords:

Osteoarthritis (OA)

Articular cartilage

Light-emitting diodes (LEDs)

Light therapy

Anterior cruciate ligament transection (ACLT)

### ABSTRACT

**Objective:** The objective of this study was to evaluate whether light-emitting diodes (LEDs) could be effective in a noninvasive, therapeutic device for the treatment of osteoarthritic (OA) knee joints.

**Design:** Five weeks following the anterior cruciate ligament transection (ACLT) of mature New Zealand White rabbits, the animal knees were exposed to LED stimulation at intervals of 10 min/day, 5 days/week for 5 weeks in the experimental group ( $n = 7$ ). The device used high intensity red and infrared (IR) LEDs with a total amount of energy delivered to the skin of 2.4 J/cm<sup>2</sup>. Animals were sacrificed at 9 weeks postoperatively. Femoral surface gross morphology was evaluated with a modified Outerbridge classification and mRNA expression of catabolic and anabolic markers from femoral condyle cartilage and synovial tissue was assessed using RT-PCR. A control group was harvested 9 weeks following untreated ACLT.

**Results:** Gross morphometry of the control group showed four Grade II, two Grade III and one Grade IV (average 2.6) condyles macroscopically. The experimental group showed two Grade I and five Grade II (average 1.7) (Table 1). mRNA expression of aggrecan in the cartilage showed no difference between the groups, however type II collagen expression increased in the experimental group compared with control. TNF- $\alpha$  expression was significantly decreased in the experimental group compared to control.

**Conclusions:** There was general preservation of the articular surface and decreased levels of inflammation in the osteoarthritic joints with the application of LED therapy. This may provide potential application as a noninvasive treatment.

© 2011 Published by Elsevier Masson SAS.

## 1. Introduction

Osteoarthritis (OA) is one of the most common diseases of aging, characterized as articular cartilage and underlying subchondral degeneration, with more than 20 million people affected in the United States [1]. OA causes joint pain and a limitation of joint range of motion (ROM), with the end stage resulting in decreased quality of life (QOL). For patients with advanced OA, however, surgical options are available. Osteoarthritic cartilage may be repaired by chondroplasty, drilling and microfracture or it may be replaced through autologous or allogenic osteochondral transplantations in an attempt to remodel the joints to their original morphometry [2–8]. Artificial joint replacement and arthrodesis are salvage procedures for severe osteoarthritic joints [9], and autologous chondrocyte implantation (ACI) is used as a cartilage reconstruction trial [10].

Early OA is usually treated by controlling pain and improving ROM. Conservative procedures begin with weight loss, ROM exercises, muscle stretching and strengthening, followed by medication and intra-articular injections of hyaluronic acid, analgesics and traditional NSAIDs. Long-term use of these drugs may increase gastric mucosal damage and cardiovascular disease [11]. Injection of hyaluronan has been shown to improve joint lubrication and decrease pain [12], however the effectiveness diminishes with time, and repetition can cause joint infection. A long-lasting, noninvasive procedure to provide anti-inflammation and preserve articular cartilage in early OA is therefore clinically desirable.

Light amplification by stimulated emission of radiation (LASER) treatment has been reported to improve wound healing, including increase of cell proliferation, collagen synthesis and growth factor production. The LASER does, however, have limitations in wavelength capacities and beam widths. An optimal wavelength of LASER for each tissue may be difficult for larger areas, and heat productions from LASER light could damage tissue [13].

Light-emitting diodes (LEDs) are complex semiconductors that convert electrical current into incoherent narrow-spectrum light.

\* Corresponding author. Tel.: +1 85 85 34 26 76; fax: +1 85 85 34 53 04.

E-mail addresses: yasushi@sj8.so-net.ne.jp (Y. Oshima), rdcoutts@aol.com (R.D. Coutts), nbadlani@gmail.com (N.M. Badlani), rhealey@ucsd.edu (R.M. Healey), fshepherd@ucsd.edu (D. Amiel).

LEDs are available at wavelengths ranging from ultraviolet (UV) to visible to near infrared (NIR) bandwidths (247 to 1300 nm). The National Aeronautics and Space Administration (NASA) has reported on the acceleration of plant growth and wound healing following exposure to LEDs. This has led to investigations into nonthermal therapy, especially in dermatology, leading to its approval as a nonsignificant risk procedure for humans by the Food and Drug Administration (FDA) [14].

We hypothesize that LED treatments can penetrate into joints, stimulate the inside of the joint cavity and articular surface, and have the potential to repair OA. The objective of this study was to evaluate the effect of LED light therapy on osteoarthritic knee joints using the anterior cruciate ligament transection (ACLT) model of OA *in vivo*.

## 2. Materials and methods

### 2.1. Animals

A total of 14 skeletally mature, female New Zealand White rabbits (9–15 months old weighing 3.5 to 4.5 kg) with closed epiphyses were used for both control and experimental evaluation ( $n = 7$  for each group). All procedures conformed to the guidelines of the University's Animal Subjects Committee and the American Association for Accreditation of Laboratory Animal Care.

### 2.2. Osteoarthritic knee joint model

The study animals were given presurgical general anesthesia injections of 35 mg/kg ketamine and 5 mg/kg xylazine intramuscularly. An anesthesia machine was attached to a facemask delivering 1–2% isoflurane for maintenance of anesthesia during surgery. The central part of the right leg was shaved and draped in sterile fashion using betadine. A 3 cm anterior midline incision was made through the skin of the knee, subcutaneous tissues were dissected, the joint capsule incised with a medial parapatellar retinacular approach, and the articular surfaces of the knee joint exposed. The ACL was then completely transected with a blade (Fig. 1). An intraoperative Lachman test was performed to verify that anterior instability had been created before closing the capsule with 2-0 Vicryl (Ethicon Inc. Somerville NJ) and the skin with 4-0 Vicryl. Previous studies have shown that this method produces a reliable and reproducible degradation of articular cartilage after 9 weeks [15,16]. All rabbits were allowed normal cage activity after the procedure in a temperature-controlled environment with a 12 h light-dark cycle. Intramuscular bupre-

norphine was administered for at least 72 h for postoperative pain control.

### 2.3. LED therapy device and treatment

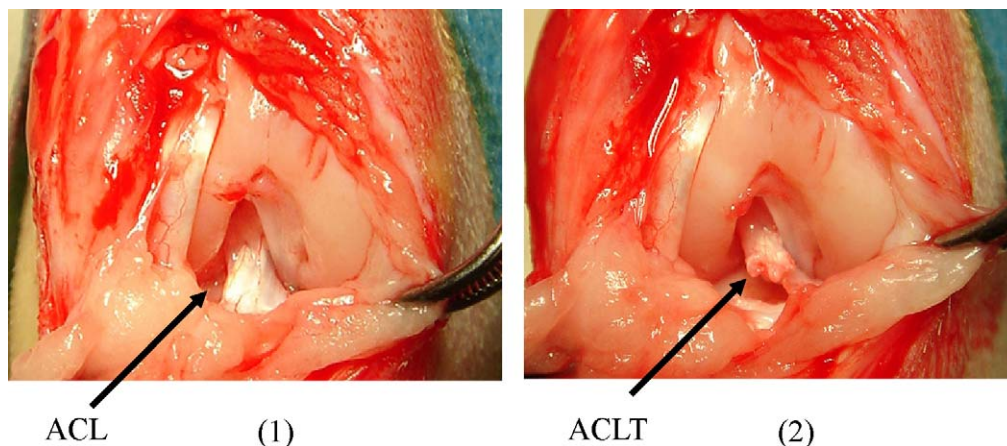
Five weeks following ACLT, LED exposure commenced at intervals of 10 min per day, 5 days per week for 5 weeks, under awake and alert conditions without sedation, in the experimental group ( $n = 7$ ). The light therapy was accomplished on the experimental knees with a very light custom-designed brace fitting comfortably over the knee and was held in place with two Velcro straps (3 M, St. Paul MN). The device applied two sets of LEDs, with wavelengths of 630 nm (red) and 870 nm (infrared: IR), LEDs mounted to the underside of the brace covered 44 cm<sup>2</sup>, and could treat the entire area of the rabbit knee joint (Fig. 2). It alternated at high frequency between two patterns of off and on diodes. The amounts of energy delivered to the skin were  $\sim 2$  J/cm<sup>2</sup> (red) and 2.5 J/cm<sup>2</sup> (IR) (Light Sciences Oncology, Inc., Snoqualmie WA).

### 2.4. Harvest tissues

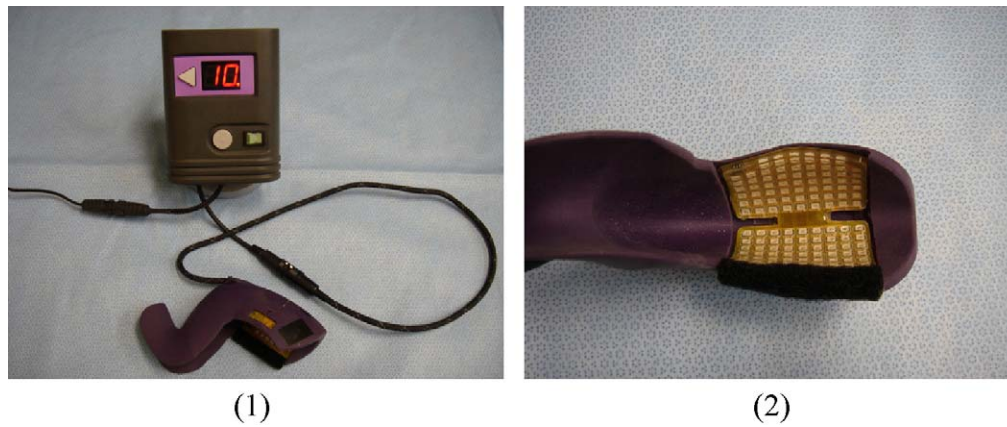Ten weeks following ACLT, and 3 days after the 5-week treatment, the treated animals ( $n = 7$ ) were sacrificed with intravenous injections of 97.8 mg/kg sodium pentobarbital via a lateral ear vein following anesthesia. In the control group without any treatment ( $n = 7$ ) the animals were sacrificed at 9 weeks following ACLT in a similar manner.

### 2.5. Gross morphology

The rabbit femurs were harvested and initially put in a phosphate buffered solution (PBS) with protease inhibitors: 2 mM disodium-ethylenediaminetetraacetic acid (Na<sub>2</sub>-EDTA), 1 mM phenylmethanesulphonyl fluoride (PMSF), 5 mM benzamidine hydrochloride (Benz-HCl), and 10 mM N-ethyl maleimide (NEM) for 1 h. The femoral condyles were then stained with india ink (Higgins Waterproof Drawing Ink, Sanford Co of Bellwood IL). The ink was applied to the surfaces of the femoral condyles with a small paintbrush and a quick rinse of sterile water. Images of the condyles were taken before and after staining with a digital camera (Nikon DX 5 megapixel) for analysis. These images were assessed for residual ink remaining on the cartilage surface by three blinded individuals. A modified Outerbridge classification score was used to grade each condyle. The score criteria consisted of: Grade 1 (intact surface) – surface appears normal and does not retain ink;



**Fig. 1.** (1) The ACL attachment of the lateral femoral condyle to the tibial plateau in a right knee joint. (2) The ACL is transected and the knee instability checked with a Lackman test.



**Fig. 2.** (1) The light therapy device. Once the button is pressed, the LED irradiation begins and continues for 10 min. (2) The LEDs are mounted to the underside of the custom-designed brace, the brace is fitted on the knee joint, and then wrapped with bandaging.

Grade 2 (minimal fibrillation) – site appears normal before staining but retains ink as elongated specks or light gray patches; Grade 3 (overt fibrillation) – the cartilage is velvety in appearance and retains ink as intense black patches; or Grade 4 (erosion) – loss of cartilage exposing the underlying bone. Using these grades, an average for each group was calculated [15,17,18].

#### 2.6. Reverse transcriptase-polymerase chain reaction (RT-PCR) technique

Anabolic and catabolic pathways in the osteoarthritic joints were also examined. Articular cartilage of the lateral femoral condyle and synovial tissue around the knee joints was shaved and the mRNA harvested using RNeasy Mini Kit (Qiagen Inc., Valencia CA).

The mRNA expressions of various markers were evaluated by RT-PCR using glyceraldehyde-3-phosphate dehydrogenase (GAPDH) as an internal control gene, type II collagen and aggrecan as anabolic markers of articular cartilage, interleukin-1 beta (IL-1 $\beta$ ) and tumor necrosis factor-alpha (TNF- $\alpha$ ) as inflammatory markers, and matrix metalloproteinase-3 (MMP-3) and MMP-13 as catabolic markers of cartilage. Based on the published sequences, PCR primers were constructed (see primer sequences: Table 1).

National Institute of Health (NIH) image analysis software (version 1.61, Natl Inst Health, Bethesda MD) was used to quantitatively scan RT-PCR profiles following agarose gel electrophoresis and ethidium bromide visualization. The relative mean density was measured over a fixed gray scale range after correction

for background. All values were normalized to GAPDH, data expressed as mean mRNA expression  $\pm$  standard deviation (SD), and evaluated with a two-tailed Student's *t*-test assuming equal variances (statistical significance  $P < 0.05$ ).

### 3. Results

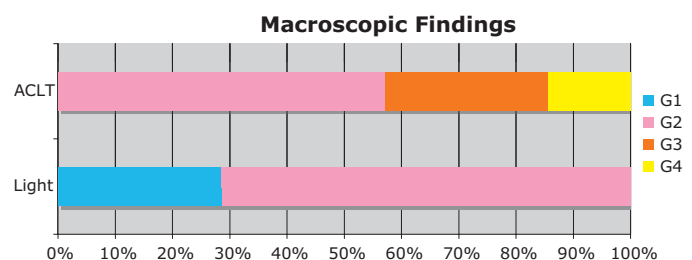
The attached LED knee device alternated between a wavelength of red (630 nm) and IR (870 nm). The peak irradiance of red is 20 mW/cm<sup>2</sup> and IR is 25 mW/cm<sup>2</sup>. This device applied energy in pulsed modes with a duty cycle of 16%. The average irradiance was then 3.2 mW/cm<sup>2</sup> for red and 4 mW/cm<sup>2</sup> for IR. With a daily irradiation time of 10 min, the daily energy dose applied of red is 2 J/cm<sup>2</sup> and IR 2.5 J/cm<sup>2</sup>. Because the treated area is 44 cm<sup>2</sup>, the total daily dose of red is 88 J and of IR is 110 J. Rabbits of both groups showed no remarkable knee joint swelling or infective symptoms. Compared to the control group, there were no remarkable side effects seen on the knee joints in the experimental group.

#### 3.1. Gross morphology

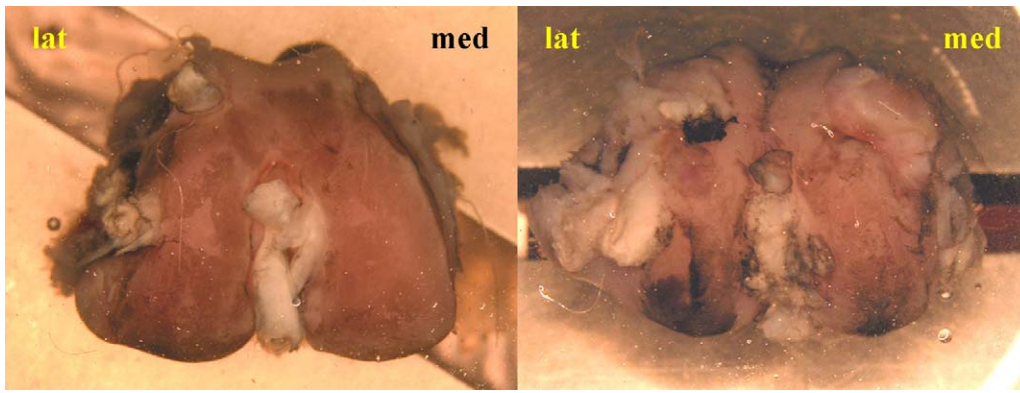
The interobserver differences in morphological grading were not significant. Macroscopically, the control group presented with four Grade II, two Grade III and one Grade IV condyles (average was 2.6) (Fig. 3). The femurs in Grade II showed slight fibrillation in both medial and lateral condyles. Grade III femurs showed slight fibrillation in the medial condyles and overt fibrillation in the lateral condyles. These degenerative patterns were more pronounced in Grade IV condyles where the overt fibrillation in the medial condyle and articular cartilage defects were present in the lateral condyles (Fig. 4).

**Table 1**  
Primer sequencing.

The sequences of primers	
GAPDH: Sense	5'-TCA CCA TCT TCC AGG AGC GA-3'
Anti sense	5'-CAC AAT GCC GAA GTG GTC GT-3'
Type II collagen: Sense	5'-AAC TGG TGG AGC AGC AAG AG-3'
Anti sense	5'-CTG CAG CAC GGT ATA GGT GA-3'
Aggrecan: Sense	5'-GAG GTC GTG GTG AAA GGT GT-3'
Anti sense	5'-GTG TGG ATG GGG TAC CTG AC-3'
MMP-3: Sense	5'-GCC AAG AGA TGC TGT TGA TG-3'
Anti sense	5'-AGG TCT GTG AAG GCG TTG TA-3'
MMP-13: Sense	5'-AAC GAG GAT GAT GAT TTG GTC CG -3'
Anti sense	5'-TTG GCC AGG AGG AAA AGC GTG AG -3'
IL-1 $\beta$ : Sense	5'-TGC AAC ACC TGG GAT GAC TA-3'
Anti sense	5'-GGC CAC AGG TAT CTT GTC GT-3'
TNF- $\alpha$ : Sense	5'-ATG GTC ACC CTC AGA TCA GC-3'
Anti sense	5'-TGA CCT TGT TCG GGT AGG AG-3'



**Fig. 3.** Results of macroscopic findings: There were four Grade II, two Grade III and one Grade IV in the control group. There were one Grade I, and five Grade II in the experimental group.

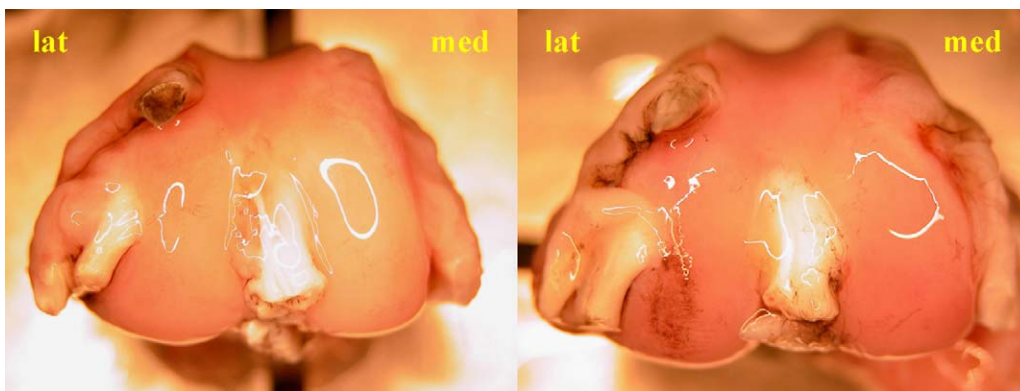


**Fig. 4.** Macroscopic findings of femurs in the control group: Minimal fibrillation was shown on the articular surface and graded as Group II (left). Erosion of the surface was detected and graded as Group IV (right).

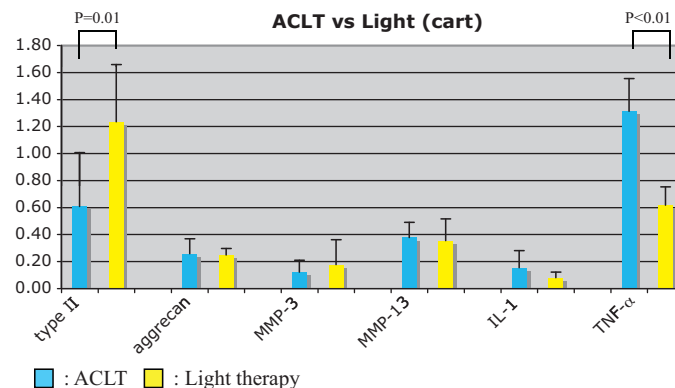
In the experimental group, after 5 weeks of treatment with the light brace, there were two Grade I and five Grade II (average 1.7) knees. For the Grade II condyles, one had minimal fibrillation only in the medial condyle and another had minimal fibrillation only in the lateral condyle of the femur. The remaining three Grade II knees showed minimal fibrillation in the medial and slight fibrillation in the lateral femoral condyles. There were two out of seven rabbits without any fibrillation in the femoral condyles (Grade I), and no severe osteoarthritic joints in the experimental group (Grades III and IV) as seen in Fig. 5.

### 3.2. RT-PCR

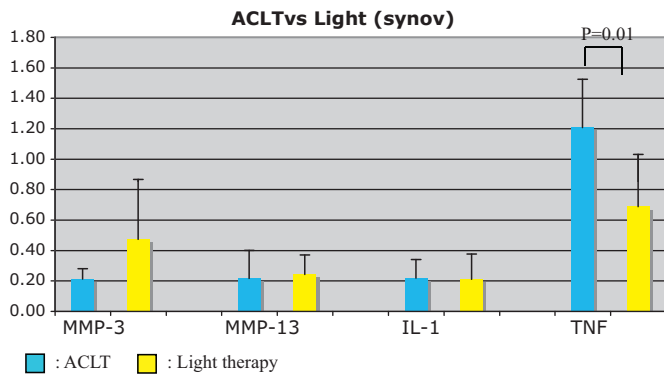
Articular cartilage from the femurs of both experimental and treated knees showed no difference in mRNA expression of aggrecan. Type II collagen expression, however, was observed to be increased in the experimental group compared to control ( $P = 0.01$ ). The expressions of MMP-3, MMP-13, and IL-1 $\beta$  in the cartilage showed no differences between the groups, however TNF- $\alpha$  expression was decreased in the experimental group compared to control ( $P < 0.01$ ) (Fig. 6).



**Fig. 5.** Macroscopic findings of femurs in the experimental group: With a smooth surface and no staining by india ink these knees were graded as Group I (left). Minimal fibrillation shown on the surface was graded as Group II (right).



**Fig. 6.** mRNA expression in the articular cartilage tissue samples: the mRNA expression of type II collagen was significantly increased in the experimental group compared to control ( $P = 0.01$ ). TNF- $\alpha$  expression, however, was significantly decreased in the experimental group compared to the control ( $P < 0.01$ ).



**Fig. 7.** mRNA expression in the synovial tissue samples: The mRNA expression of TNF- $\alpha$  was significantly decreased in the experimental group compared to the control ( $P = 0.01$ ).

In the synovial tissue the expressions of MMP-3, MMP-13, and IL-1 $\beta$  showed no differences between groups. There was a decrease, however, in TNF- $\alpha$  expression of the experimental group compared to control ( $P = 0.01$ ) (Fig. 7).

#### 4. Discussion

OA is one of the most common diseases affecting articular cartilage. While there are several surgical options for OA, there are relatively few conservative, noninvasive procedures effective at treating OA clinically. Preserving and producing cartilage noninvasively is desirable, especially for early OA. ROM, muscle stretching and strengthening are the first steps for treating early OA as a noninvasive treatment. These exercises may include cryotherapy, thermotherapy and electrical stimulation. Cryotherapy induces vasoconstriction to limit tissue edema formation and also has an anti-inflammatory effect presumably lowering joint temperature, collagenase activity, and white blood cell count within arthritic joints [19]. It has also been reported to have a statistically significant beneficial effect on joint ROM, function, stretching and decrease in swelling [20]. Thermotherapy is used to increase tissue elasticity and provide analgesia [21]. Therapeutic ultrasound is often administered with the benefit of an analgesic property due to its deep heating modality [22]. Electrical stimulation is applied for pain relief and to improve function [23]. The effect of these therapies has not been clearly analyzed, making the choice of these treatments not fully understood, nor which temperature would benefit the OA joints.

In this study, LED therapy applied to an OA knee model showed a protective effect on the destabilized articular cartilage surface compared to the nontreatment group. The mRNA expressions of type II collagen in the cartilage was seen to be upregulated, and TNF- $\alpha$  in both cartilage and synovial tissues was downregulated.

LED therapy has been reported as nonthermal light therapy without adverse reactions [24]. The acceleration of burn healing potential has been shown [25], as well as the increase in growth of various cell lines such as fibroblasts, osteoblasts, skeletal muscle cells and epithelial cells [13]. The upregulation of type I procollagen has also been demonstrated with LED application [24]. The specific effects of LED therapy on chondrocytes have not yet been examined, however the increase in type II collagen synthesis was confirmed in this study, and thus LEDs may have a potential to stimulate chondrocyte growth.

The downregulation of cyclooxygenase enzyme and the inhibition of prostaglandin E2 synthesis has indicated a potential anti-inflammatory potential of LED therapy [26]. The reduction of MMPs has also been reported [24,27]. There was no decrease in

either MMP-3 or MMP-13 expressions observed in this study. Other MMPs have yet to be evaluated; however TNF- $\alpha$  expression was significantly downregulated by the treatment, therefore demonstrating potential as an anti-inflammatory procedure.

LED therapy has been applied in clinical trials, especially in dermatology. The use of LEDs has been applied for treating rosacea, preventing sunburn, hyperpigmentation and scars, and the results in humans are encouraging [14]. To achieve successful results with LED therapy, it is important to determine the appropriate parameters of wavelength, dose, intensity, irradiation time and continuous or pulsed modes. De Morias et al. [28] examined the anti-inflammatory effect of low-level laser therapy (LLLT) and LED therapy for arthritic knee joints. They concluded that LLLT could reduce inflammatory signs more effectively than LED therapy, however they indicated that new inquiries should be carried out to evaluate the effectiveness of LEDs with different parameters.

Different wavelengths have different chromophores and can have various effects on tissues. In general, LEDs of longer wavelength can penetrate deeper into tissues. Red light has also been shown to be more successful at affecting deeper targets than smaller wavelengths [29–31]. The red and infrared wavelengths applied through LED therapy were adequate for knee joint tissue (i.e. cartilage and synovial tissue) of the rabbit.

The effect of the cellular response to pulsed wave versus continuous wave has not been fully evaluated. Because the pulsed wave was thought to stimulate more collagen production than continuous wave, the pulse wave was applied [14]. This may have contributed to the increased expression of type II collagen. If the light intensity is lower than the physiological threshold value for a given target, it does not produce photostimulatory effects, even when irradiation time is extended [14]. Therapeutic outcomes are dependent upon these parameters, making it necessary to find the optimal LED and dose for the intended treatment. The treatment group responded with our applied intensity levels and wavelengths, while the nontreatment groups demonstrated significantly different outcomes.

This study has examined the effect of LED irradiation on OA knees. While there is still a need to examine the detail of the function and mechanism, as well as the optimal conditions for articular cartilage application, there appears to be a capacity to accelerate the regeneration of articular cartilage with LED therapy. Therefore, this treatment may offer the benefit of an alternative, noninvasive procedure to treat OA joints at outpatient clinics.

#### 5. Conclusions

With LED light therapy, the *in vivo* cartilage surface was preserved macroscopically and the mRNA expression of type II collagen was upregulated in the treated group. Inflammation levels appeared to decrease in both cartilage and synovial tissues at the mRNA level, and LED light therapy shows a potential for anti-inflammatory function which may preserve and potentially repair articular cartilage. As such, this procedure deserves more study as a noninvasive treatment of OA joints clinically.

#### Disclosure of interest

The authors declare that they have no conflicts of interest concerning this article.

#### Acknowledgement

We thank Light Sciences Oncology, Inc., Snoqualmie (WA) for providing financial support for this project, and Anthony J. Robins, M.D. for his scientific contributions.

## References

- [1] Lawrence RC, Helmick CG, Arnett FC, Deyo RA, Felson DT, Giannini EH, et al. Estimates of the prevalence of arthritis and selected musculoskeletal disorders in the United States. *Arthritis Rheum* 1998;41(5):778–99.
- [2] Johnson LL. Arthroscopic abrasion arthroplasty historical and pathologic perspective: present status. *Arthroscopy* 1986;2(1):54–69.
- [3] Steadman JR, Rodkey WG, Rodrigo JJ. Microfracture: surgical technique and rehabilitation to treat chondral defects. *Clin Orthop Relat Res* 2001;Suppl. 391:S362–9.
- [4] Pridie KH. A method of resurfacing osteoarthritic knee joints. *J Bone Joint Surg* 1959;41B:618–9.
- [5] Mitchell N, Shepard N. The resurfacing of adult rabbit articular cartilage by multiple perforations through the subchondral bone. *J Bone Joint Surg Am* 1976;58(2):230–3.
- [6] Matsusue Y, Yamamuro T, Hama H. Arthroscopic multiple osteochondral transplantation to the chondral defect in the knee associated with anterior cruciate ligament disruption. *Arthroscopy* 1993;9(3):318–21.
- [7] Hangody L, Kish G, Kárpáti Z, Szerb I, Udvarhelyi I. Arthroscopic autogenous osteochondral mosaicplasty for the treatment of femoral condylar articular defects. A preliminary report. *Knee Surg Sports Traumatol Arthrosc* 1997;5(4):262–7.
- [8] Görtz S, Bugbee WD. Allografts in articular cartilage repair. *J Bone Joint Surg Am* 2006;88(6):1374–84.
- [9] Gidwani S, Fairbank A. The orthopaedic approach to managing osteoarthritis of the knee. *Br Med J* 2004;20(329(7476)):1220–4.
- [10] Brittberg M, Lindahl A, Nilsson A, Ohlsson C, Isaksson O, Peterson L. Treatment of deep cartilage defects in the knee with autologous chondrocyte transplantation. *N Engl J Med* 1994;6(331(14)):889–95.
- [11] Clegg DO, Reda DJ, Harris CL, Klein MA, O'Dell JR, Hooper MM, et al. Glucosamine, chondroitin sulfate, and the two in combination for painful knee osteoarthritis. *N Engl J Med* 2006;23(358(8)):795–808.
- [12] Puhl W, Bernau A, Greiling H, Köpcke W, Pörringer W, Steck KJ, et al. Intra-articular sodium hyaluronate in osteoarthritis of the knee: a multicenter, double-blind study. *Osteoarth Cartilage* 1993;1(4):233–41.
- [13] Whelan HT, Smits Jr RL, Buchman EV, Whelan NT, Turner SG, Margolis DA, et al. Effect of NASA light-emitting diode irradiation on wound healing. *J Clin Laser Med Surg* 2001;19(6):305–14.
- [14] Barolet D. Light-emitting diodes (LEDs) in dermatology. *Semin Cutan Med Surg* 2008;27(4):227–38.
- [15] Yoshioka M, Coutts RD, Amiel D, Hacker SA. Characterization of a model of osteoarthritis in the rabbit knee. *Osteoarthritis Cartilage* 1996;4(2):87–98.
- [16] Sah RL, Yang AS, Chen AC, Hant JJ, Halili RB, Yoshioka M, et al. Physical properties of rabbit articular cartilage after transection of the anterior cruciate ligament. *J Orthop Res* 1997;15(2):197–203.
- [17] Meachim G, Fergie IA. Morphological patterns of articular cartilage fibrillation. *J Pathol* 1975;115(4):231–40.
- [18] Badlani N, Inoue A, Healey R, Coutts R, Amiel D. The protective effect of OP-1 on articular cartilage in the development of osteoarthritis. *Osteoarth Cart* 2008;16(5):600–6 [Erratum in: *Osteoarth Cart* 2009;17(4):556].
- [19] Oosterveld FG, Rasker JJ. Effects of local heat and cold treatment on surface and articular temperature of arthritic knees. *Arthritis Rheum* 1994;37(11):1578–82.
- [20] Brosseau L, Yonge KA, Robinson V, Marchand S, Judd M, Wells G, et al. Thermotherapy for treatment of osteoarthritis. *Cochrane Database Syst Rev* 2003;4:CD004522.
- [21] Lehmann JF, Masock AJ, Warren CG, Koblanski JN. Effect of therapeutic temperatures on tendon extensibility. *Arch Phys Med Rehabil* 1970;51(8):481–7.
- [22] Gam AN, Johannsen F. Ultrasound therapy in musculoskeletal disorders: a meta-analysis. *Pain* 1995;63(1):85–91.
- [23] Zizic TM, Hoffman KC, Holt PA, Hungerford DS, O'Dell JR, Jacobs MA, et al. The treatment of osteoarthritis of the knee with pulsed electrical stimulation. *J Rheumatol* 1995;22(9):1757–61.
- [24] Barolet D, Roberge CJ, Auger FA, Boucher A, Germain L. Regulation of skin collagen metabolism in vitro using a pulsed 660 nm LED light source: clinical correlation with a single-blinded study. *J Invest Dermatol* 2009;129(12):2751–9.
- [25] Al-Watban FA, Andres BL. Polychromatic LED therapy in burn healing of non-diabetic and diabetic rats. *J Clin Laser Med Surg* 2003;21(5):249–58.
- [26] Lim W, Lee S, Kim I, Chung M, Kim M, Lim H, et al. The anti-inflammatory mechanism of 635 nm light-emitting-diode irradiation compared with existing COX inhibitors. *Lasers Surg Med* 2007;39(7):614–21.
- [27] Fisher GJ, Kang S, Varani J, Bata-Csorgo Z, Wan Y, Datta S, et al. Mechanisms of photoaging and chronological skin aging. *Arch Dermatol* 2002;138(11):1462–70.
- [28] de Moraes NC, Barbosa AM, Vale ML, Villaverde AB, de Lima CJ, Cogo JC, et al. Anti-inflammatory effect of low-level laser and light-emitting diode in zymosan-induced arthritis. *Photomed Laser Surg* 2010;28(2):227–32.
- [29] Karu TI, Pyatibrat LV, Afanasyeva NI. Cellular effects of low power laser therapy can be mediated by nitric oxide. *Lasers Surg Med* 2005;36(4):307–14.
- [30] Kalka K, Merk H, Mukhtar H. Photodynamic therapy in dermatology. *J Am Acad Dermatol* 2000;42(3):389–413.
- [31] Simpson CR, Kohl M, Essenpreis M, Cope M. Near-infrared optical properties of ex vivo human skin and subcutaneous tissues measured using the Monte Carlo inversion technique. *Phys Med Biol* 1998;43(9):2465–78 [Erratum in: *J Am Acad Dermatol* 2000;43(4):609; *J Am Acad Dermatol* 2001;44(1):150].